

Early Dislodgement of Drug-Eluting Coronary Stent from The Balloon Catheter

Orhan Dogdu¹, Mikail Yarlioglu², Erol Tulumen¹, Ali Taner¹

ABSTRACT

Early complete dislodgement of stent from the balloon catheter is a rare complication and may lead to severe coronary ischaemia. In such cases, the first treatment option is the retrieval of the material, while another option is to squeeze the undeployed stent into vessel wall by inflating the balloon. Although several methods and devices are available for stent removal, retrieval procedure is likely to be unsuccessful in many cases. In this paper, we presented two cases of early dislodgement of drug-eluting coronary stents during coronary angioplasty procedure and other methods subsequently performed in such cases.

Key words: Drug-eluting stent, complication, stent dislodgement

Balon Kateterden İlaç Kaplı Stentin Erken Ayrılması

ÖZET

Stentin balon üzerinden erken ayrılması nadir görülen bir komplikasyondur ve ciddi koroner iskemiye yol açabilir. Bu durumda materyalin geri alınması ilk tedavi seçeneğidir. Bir başka yöntem ise açılmamış durumdaki stentin akımı bozmadan bulunduğu ortamda stabilize edilmesidir. Ayrılan stentin ortamdaki uzaklaştırılması için kullanılan birçok metod ve cihaz olmasına rağmen vakaların çoğunda geri alma işlemi başarısız olmaktadır. Bu yazıda, koroner anjiyoplasti işlemi sırasında stentin erken ayrılması ve sonrasında uygulanan yöntemleri ele alan iki olgu sunuldu.

Anahtar kelimeler: İlaç salımlı stent, komplikasyon, stent ayrılması

INTRODUCTION

In parallel with the improving intracoronary stent technology, procedure-related complication rate has been shown to be reduced. Complete dislodgement of drug-eluting coronary stent from the balloon catheter into the coronary artery is a rarely seen complication. As it may lead to severe myocardial ischemia, it is critical to retrieve the material (1). On the other hand, several methods are used for stent removal. In this paper, we presented two cases of early dislodgement of drug-eluting coronary stents into the coronary artery during coronary angioplasty procedure and other methods subsequently performed in such cases.

¹Yozgat State Hospital, Department of Cardiology, Yozgat, Turkey, ²Sorgun State Hospital, Department of Cardiology, Yozgat, Turkey

Received: 24.12.2011, Accepted: 30.07.2012

CASE 1

A 64-year-old woman who presented with chest pain was admitted with the diagnosis of acute coronary syndrome. The history of the patient revealed hypertension and type II diabetes mellitus. Coronary angiography showed a 30% stenosis in the mid left anterior descending (LAD) artery, 95% stenosis of the obtuse marginal branch of circumflex (Cx) artery, and 30% stenosis of the right coronary artery (RCA) ostium. As a result, an intervention was performed on Cx artery. Following the predilatation, a balloon-expandable stent (2,5 x 24 mm, drug-eluting) was advanced through the left main coronary artery. During the procedure, the stent was

Dr. Orhan Dođdu
Yozgat State Hospital, Department of Cardiology, 66100 Yozgat, Turkey
Tel: 905335045065, Fax: 903524373408
E-mail: orhandogdu@yahoo.com

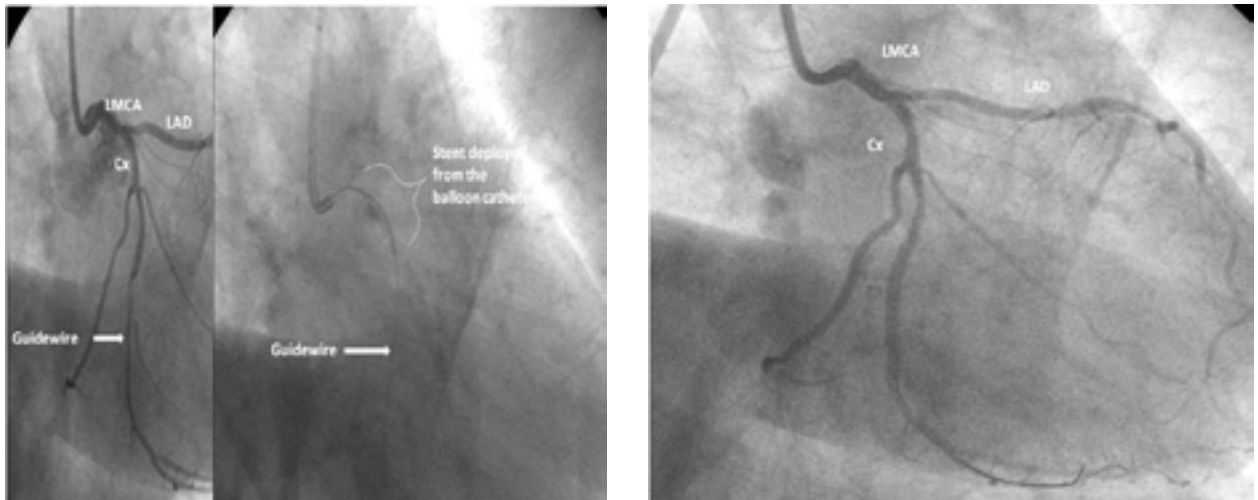


Figure 1. a. Early dislodgement of stent from the balloon catheter in the LMCA before Cx artery stenosis. b. Post-procedure image

dislodged from the balloon catheter (Figure 1a). When the redeployment of the balloon catheter into the stent failed, a smaller one (1,5 x 10 mm) was inserted. This new balloon catheter was inflated at a pressure of 4 atm and retrieved carefully. After the stent was deployed, the procedure was completed (Figure 1b).

CASE 2

A-70-year-old woman who presented with chest pain with family history of hypertension and previous coronary artery bypass grafting surgery was admitted to a healthcare center. The patient was scheduled for coronary angiography with the diagnosis of acute coronary syndrome. Following coronary angiography, an intervention was planned for the lesion located in the mid right coronary artery (80% stenosis). During coronary angioplasty, the stent was not able to be advanced through the lesion and was retrieved along with the guidewire.

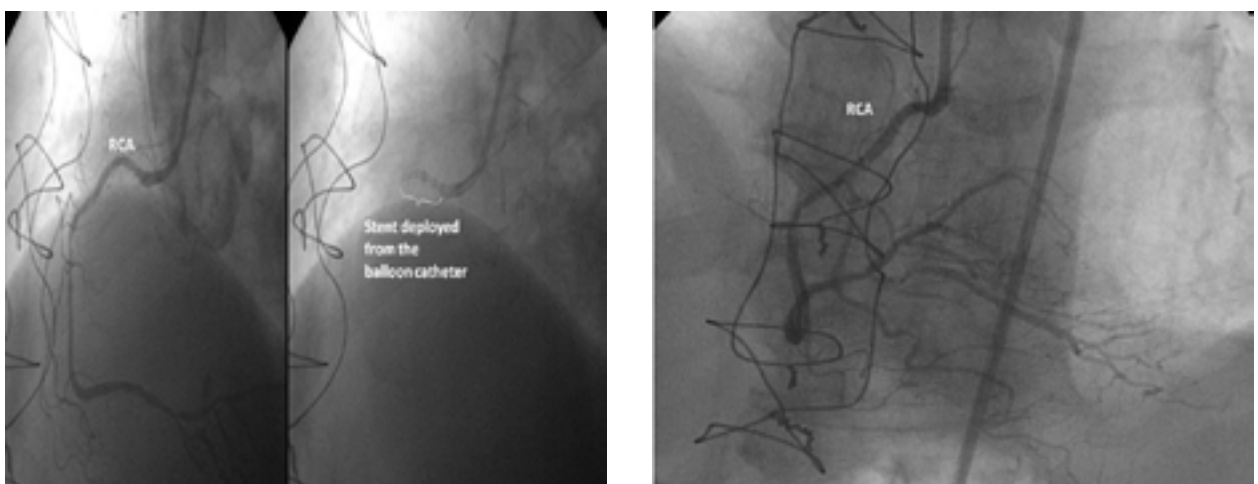


Figure 2. a. Early dislodgement of stent from the balloon catheter in the RCA proximal. b. Post-procedure image

During retrieval, the stent was dislodged from the balloon catheter into the right coronary artery (Figure 2a). The patient who was referred to our hospital immediately was sent to catheterization lab and an intervention was performed using foreign body forceps to retrieve the dislodged stent located in the right coronary artery proximal. When the intervention failed, the guidewire was threaded through the stent and advanced to the tip of the stent. The balloon catheter was inflated at a pressure of 4 atm and the dislodged stent was retrieved gently, squeezing it into the vessel wall. The stent and balloon catheter, then, were retrieved carefully. A new stent was dislodged, before the procedure was completed (Figure 2b).

DISCUSSION

Early dislodgement of the stent from the balloon catheter is most commonly seen with particularly first-generation coronary stents. The prevalence of this complication ranges from 0.9% to 8.4% (1,2). The exact prevalence of this complication using with the last-generation and particularly drug-eluting coronary stents has not been established yet. In a retrospective study, Bolte et al. estimated the prevalence of early dislodgement of the stent as 1.7% (3). The prevalence of stent embolization with the first-generation stents (Palmaz-Schatz, Wiktor) loaded by the balloon catheter manually was reported to be higher. In Bolte's study, dislodged stents were attempted to be redeployed in 60% of the patients, however it was successful only ~30%. In 6 patients, stent was squeezed by inflating the balloon or fixed into vessel wall using another stent. The complication rate including death, myocardial infarction (MI), neurological deficit was also higher in the patients whose stents were not able to be retrieved from the coronary artery. However, last-generation drug-eluting stents were used in our study, without leading to any complication including death and MI, as the retrieval procedure was successful.

Early dislodgement of the coronary stent from the balloon catheter is most commonly seen while advancing through complicated, calcific and angled stenoses and retrieving the guidewire (4). The coronary stent was dislodged from the balloon catheter while advancing through the left main coronary artery before reaching lesion in the Cx artery in the Case 1, whereas the stent was dislodged from the balloon catheter in the proximal

region while retrieving the guidewire in the mid RCA in the Case 2.

As an unexpanded intracoronary stent may lead to myocardial ischemia, it should be retrieved immediately. Many approaches are available for stent removal including surgical removal or bypass surgery. On the other hand, currently, interventional techniques are often used before surgery. One of these techniques is advancing another guidewire throughout stent filaments and squeezing the dislodged stent into the vessel wall before the guidewire is retrieved carefully (5). Another technique is also advancing another guidewire outer region of the stent and squeezing the dislodged stent into the vessel wall by inflating the balloon and retrieving the material similar to Fogarty's method (6). In addition, dislodged stents can be retrieved using foreign body forceps or fixing the stent into the vessel wall by threading the guidewire outer region of the stent or inflating the balloon, preserving the blood flow in the circulation (7). Unlike all of these techniques, we used a new balloon catheter which was advanced through the guidewire and inflated at a lower pressure and it was retrieved carefully in the Case 1. In the Case 2, the guidewire was also threaded through the stent and advanced to the tip of the stent. The balloon catheter was then inflated at a lower pressure and all materials were retrieved carefully.

Today, early dislodgement of coronary stent from the balloon catheter is a rare complication. In such cases, the primary approach should be retrieval of the material. Given the fact that complications including death, MI, neurological deficit are more common in patients with dislodged intracoronary stents, it is critical to report the cases and treatment options. In the light of our experience and discretion in both cases, we conclude that advancing a new and smaller balloon catheter through the stent and squeezing the dislodged stent in the inner or the distal region by inflating the balloon and retrieving the material is an effective technique for dislodged stent removal and we recommend this approach in such cases.

REFERENCES

1. Schatz RA, Baim DS, Leon M, et al. Clinical experience with the Palmaz-Schatz coronary stent: Initial results of a multicenter study. *Circulation* 1991; 83: 148-61

2. Carrozza JP, Kuntz RE, Levine MJ, et al. Angiographic and clinical outcome of intracoronary stenting: Immediate and long-term results from a large single-center experience. *J Am Coll Cardiol* 1992; 20: 328-37
3. Bolte J, Neumann U, Pfafferott C, et al. Incidence, management and outcome of stent loss during intracoronary stenting. *Am J Cardiol* 2001; 88: 565-7
4. Alfonso F, Martinez D, Hernandez R, et al. Stent embolization during intracoronary stenting. *Am J Cardiol* 1996; 78: 833-5
5. Veldhuijzen FL, Bonnier HJ, Michels HR, et al. Retrieval of undeployed stents from the right coronary artery: Report of two cases. *Cathet Cardiovasc Diagn* 1993; 30: 245-8
6. Cishek MB, Laslett L, Gershony G: Ballon catheter retrieval of dislodged coronary artery stents: A novel technique. *Cathet Cardiovasc Diagn* 1995; 34: 350-2
7. Foster-Smith KW, Garratt KN, Higano ST, et al. Retrieval techniques for managing flexible intracoronary stent misplacement. *Cathet Cardiovasc Diagn* 1993; 30: 63-8